

CASE REPORT

Diffuse Inflammatory Pseudotumor of the Testis, the Epididymis and the Spermatic Cord

Zsolt OROSZ¹ and István BESZNYÁK²

¹Department of Human and Experimental Tumorpathology and

²Department of Surgery

National Institute of Oncology, Budapest, Hungary

Inflammatory pseudotumors have been recognized in many parts of the body. A case of a diffuse variant which involved the testis, the epididymis and the spermatic cord is described. The patient had enlarged left testis for several months. Clinically, the lesion mimicked cancer. Histologically, the lesion contained hyalinized fibrous tissue with spindle cells, plasma cells and lymphocytes. Gradual involvement of vascular channels by the cellular elements of inflammatory pseudotumor was observed. Results of immunohistochemical studies showed a

myofibroblast differentiation in the majority of spindle cells: intense antibody staining for smooth muscle actin, muscle specific actin, and vimentin. The ultrastructural findings, intracytoplasmic filaments with dense bodies, were also consistent with the myofibroblastic nature of these cells. The histiocyte differentiation of spindle cells is questionable in our case, because only scattered histiocyte-like cells showed positivity with the KP-1 (CD-3) antibody. (Pathology Oncology Research Vol 1, No 1, 75-79, 1995)

Key words: inflammatory pseudotumor, plasma cell granuloma, testis, myofibroblast

Introduction

Inflammatory pseudotumor (IPT) constitutes a category of benign tumor-like lesions that occurs throughout the body,⁹ most commonly in the lung.^{1,7,9} These well-circumscribed, non-encapsulated lesions are composed of a mixed inflammatory infiltrate in which plasma cells and spindle cells predominate in various proportions. The mixed infiltrate also contains eosinophils, neutrophils and histiocytes. Similar lesions – either nodular or diffuse – of the paratesticular structures were described in the past as "fibroma", "pseudofibromatous periorchitis", "reactive periorchitis" and "fibrous pseudotumor."⁸ Based on Someren's¹⁰ categories, these lesions are classified as sclerosing subtype of IPT. Recently, immunohistochemical studies on IPT-s of the salivary glands¹³ and lymph nodes¹⁴ showed a biphasic spindle cell differentiation of myofibroblasts and histiocytes with variable staining for muscle-specific actin, smooth muscle actin and KP-1 (CD-3).

In our case inflammatory pseudotumor involved the testis, the epididymis and the spermatic cord. The purpose of this study was to identify the morphological, ultrastructural and immunohistochemical features of IPT, and discuss the possible pathogenesis.

Material and Methods

The surgical specimen was fixed in 10% buffered formalin and processed by standard technique to paraffin wax. The 5 µm thick sections were stained with hematoxylin and eosin and Gomori's reticulin stains. Parts of the fresh material were fixed in 2% glutaraldehyde, postfixed in 2% osmium tetroxide and embedded in araldite. Ultrathin sections were stained with lead citrate and uranyl acetate. For immunohistochemical examination, deparaffinized tissue sections were stained with a panel of mono- and polyclonal antibodies using the avidin-biotin-peroxidase method. The reagents, their sources, and dilutions are listed in *Table 1*.

Report of a case

A 63-year-old man presented a hard, slightly tender scrotal mass, of approximately 7 cm in diameter unseparable from the testis that he observed for 2 months. Further

Received: Nov 4, 1994, accepted: Febr 3, 1995

Correspondence: Zsolt OROSZ, M.D; Department of Human and Experimental Tumorpathology, National Institute of Oncology; 1122 Budapest, Ráth György u. 7-9, Hungary

physical examination and routine laboratory investigations were normal. The patient underwent a left orchiectomy. Postoperative recovery was uneventful and the patient is well without any sign of tumor one year later.

Table 1. Immunohistochemical reagents used in the study of inflammatory pseudotumor by the avidin-peroxidase method

Antibody specificity	Source	Dilution	Type of antibody
Desmin	DAKO	1:100	Monoclonal
Vimentin	DAKO	1:100	Monoclonal
S-100 protein	DAKO	1:200	Polyclonal
Factor VIIIa	BioGenex	1:1	Polyclonal
Anti-kappa, anti-lambda	BioGenex	1:1	Monoclonal
KP-1	DAKO	1:10	Monoclonal
Smooth muscle actin (1A4)	DAKO	1:50	Monoclonal
Muscle specific actin (HHF-35)	DAKO	1:50	Monoclonal

Pathological examination

Gross findings – The specimen measured 8 x 6.5 x 5 cm testis with a 7 cm spermatic cord. The tunica albuginea was intact. On the cut surface, in the center, the intact testicular parenchyma was 3 cm thick in its maximum diameter. It was surrounded, infiltrating the epididymis by 1-3 cm thick, firm to hard, opaque, yellowish-gray fasciculated tissue containing myxoid parts. Similar nodules of about 0.5 cm in diameter, each were observed in the spermatic cord near the testis.

Microscopic findings – In the center of the testis residual tubules with inhibited spermiogenesis were found. The normal areas were surrounded by hyalinized fibrous tissue.

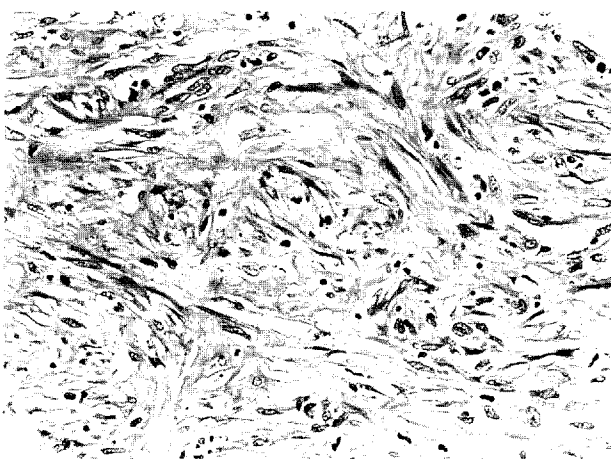


Figure 1. Fascicles of spindle cells with ill-defined storiform pattern and intercellular collagen bundles.

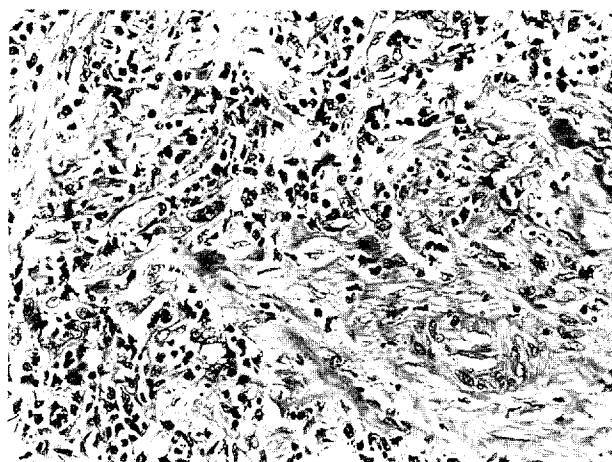


Figure 2. Myofibroblasts are intermingled with mixed inflammatory infiltration.

Proliferating spindle cells were arranged in interlacing fascicles and whorls that sometimes displayed ill-defined storiform patterns (*Fig. 1.*), without the cellular density that might lead to confusion with a malignant tumor. Cells were separated by collagen fibers of variable sizes and slit-like spaces. The nuclei showed slight polymorphy with ovoid or elongated shape, plump and pale staining, sometimes containing a single small eccentric nucleolus. Mitotic activity was inconspicuous. The cytoplasm was eosinophilic, fibrillar, and cell boundaries were indistinct. Diffuse, but variably dense mixed inflammatory infiltrate (*Fig. 2.*) was present throughout the lesion with a predominance of mononuclear cells, principally plasma cells. Occasional aggregates of mature lymphocytes without follicles were observed. A few eosinophils, neutrophils and histiocytes were also present. The process extended through the rete testis into the epididymis destroying the architecture and also appeared in small foci in the

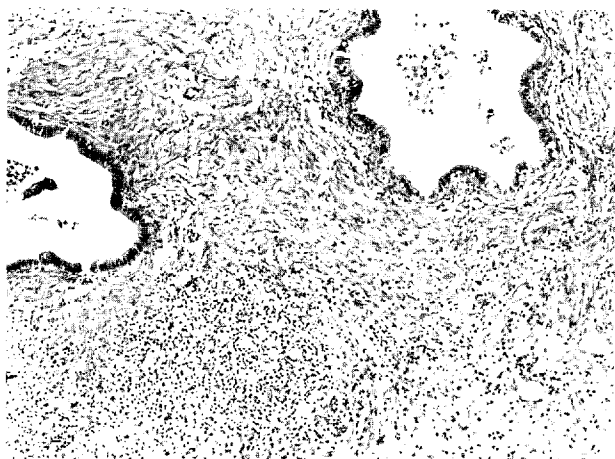


Figure 3. Cystic dilatation of tubules of the epididymis, surrounded by all elements of IPT.

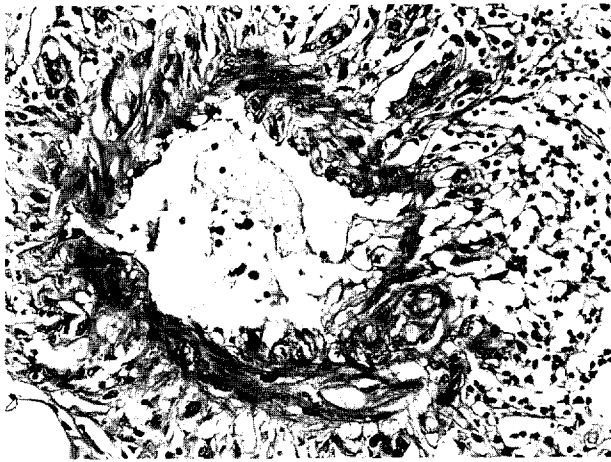


Figure 4 A. Vascular changes, Stage I. shows lymphoplasmacytic infiltration of adventitia.

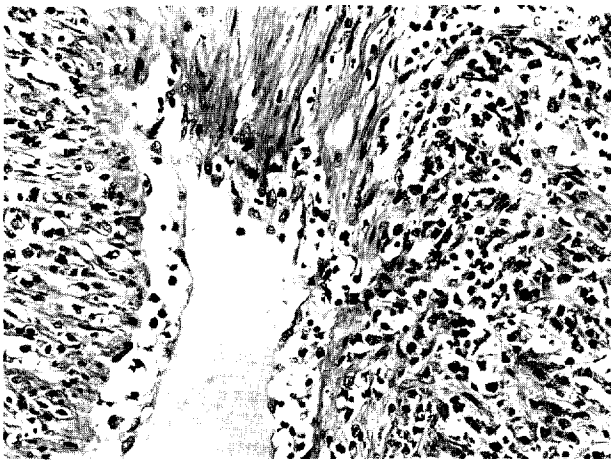


Figure 4 B. Vascular changes, Stage II. Note the permeation of the muscle wall by chronic inflammatory cells.

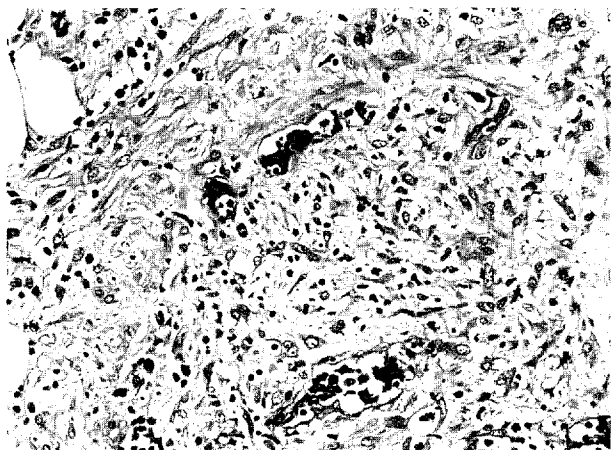


Figure 4 C. Vascular changes, Stage III. Replacement of lumina by all components of IPT. Note the small recanalizations both in the periphery and in the center.

spermatic cord. These latter lesions contained fewer collagen fibers than the testis, and lead to cystic dilatation in some of the remaining tubules of the epididymis (Fig.3.)

Two types of vascular changes were seen: a) capillary proliferation similar to granulation tissue. b) involvement of larger vessels by the inflammatory pseudotumor. The involvement of larger vessels were at different stages being present synchronously. Stage I. was the lymphoplasmacytic infiltration and capillary proliferation of the adventitia (Fig.4 A); Stage II. was the destruction of muscle coat by lymphoplasmacytic and spindle cell infiltration (Fig.4 B); and Stage III. was the obliteration of lumina by all elements of IPT (Fig.4 C) with or without recanalization. Fibrinoid vascular necrosis was not present.

Immunohistochemical findings – The primary purpose of the immunohistochemical studies was to analyze the phenotypic nature of the spindle cells that provides the largest portion of the lesion. These spindle cells showed intense (> 50% of cells) positivity for α -smooth muscle actin (1A4) (Fig.5.) and for muscle specific actin (HHF-35). No reactivity in these cells was detected for desmin, though the smooth-muscle wall of arteries was strongly positive. Vimentin was also localized to these cells. In regions of lymphoplasmacytic infiltrate, some of the scattered mononuclear cells resembling histiocytes reacted with the KP-1 antibody. In contrast, the spindle cells generally did not react with this antibody. No staining was observed for S-100 protein or Factor VIII-related antigen in cells within the lesion. Entrapped nerves and endothelial cells served as positive controls for these stainings. Spindle cells did not react with cytokeratin antibodies. Positivity for kappa and lambda chains reactions revealed the polyclonal nature of plasma cells and that of some transformed lymphocytes.

Ultrastructure – The sample contained a similar proportion of the cell types that were seen in the light microscopic specimens, with a predominance of fusiform cells. These had a cytoplasmic membrane with few out-pouchings. No intercellular junctions were demonstrable. The cytoplasm contained a well developed rough endoplasmic reticulum, a Golgi complex and bundles of filaments. The filaments situated parallel to the cell membrane, and focally made subplasmalemmal dense-bodies (Fig.6.). The nuclei showed indentations and marginated, scanty heterochromatin. The intercellular substance was rich in collagen.

Discussion

Fibrous proliferations in paratesticular tissue may present either a diffuse or a nodular pattern.^{8,11} A variety of names describing these lesions are known of which the term of fibrous pseudotumor is widely accepted. The designation of inflammatory pseudotumor (IPT) suggests a reactive lesion and reflects similarity to IPTs occurring in other parts of the body. IPTs are a morphologically diverse group of lesions




Figure 5. The majority of spindle cells are smooth muscle actin-positive.

containing a mixture of spindle cells and chronic inflammatory cells. Immunohistochemical studies of spindle cells showed expression of smooth muscle actin, muscle-specific actin, vimentin and KP-1 antigen in salivary gland¹³ and in lymph nodes.^{3,4} Based on these data, Williams et al.¹³ con-

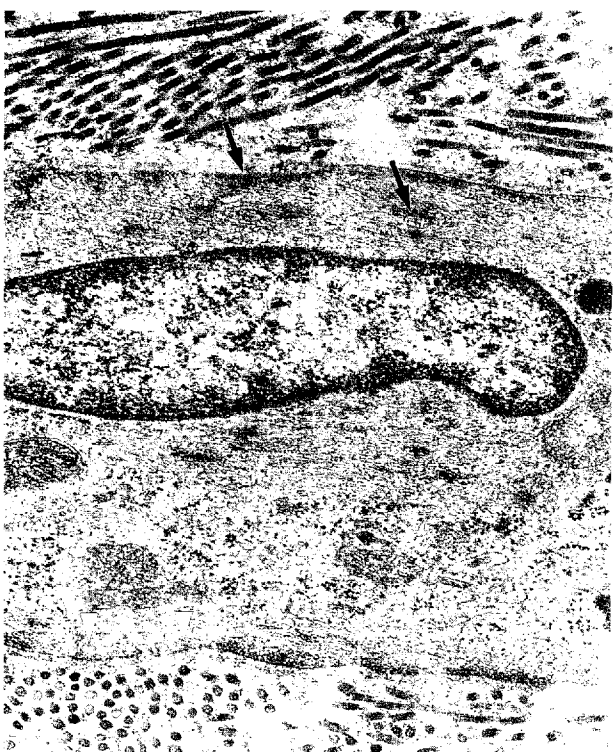


Figure 6. Detail of a spindle cell in a collagenous stroma. Features that are suggestive of myofibroblastic differentiation include thin cytoplasmic filaments with focal and subplasmalemmal densities (arrows) and micropinocytotic vacuoles (arrowheads).

cluded that spindle cells differentiated in both myofibroblastic/fibrohistiocytic pathways, while Davis et al.³ reported that the KP-1 positive and the muscle-specific/smooth muscle actin positive cells represent distinct populations. Our immunohistochemical findings did not support the hypothesis of dual phenotypic differentiation in paratesticular localization, since only scattered histiocyte-like cells expressed the KP-1 antigen, and these cells may represent only a part of the inflammatory infiltrate.

There are observations of vascular extension of IPT which can obliterate small or large vessels.^{1,12} However, the role of vascular changes, which were present in different stages in our case (especially in "younger", less hyalinized foci of the spermatic cord) is not clear in the histogenesis of IPT. The vascular damages may initiate a myofibroblast proliferation, similar to granulation tissue in the rat experimental model,² but the process in IPT progresses and the continuous myofibroblast accumulation with lymphoplasmacytic infiltration may induce further vascular changes. The steps of this vicious circle could be mediated by elements of chronic inflammatory infiltrate. The possible first event in paratesticular localization is trauma, torsion or infection, even when there are no significant anamnestic data.^{5,8,12}

In conclusion, the fibrous pseudotumor of the paratesticular area is a secondary tumor-like proliferation of myofibroblasts with extensive collagen production showing close relationship with inflammatory pseudotumor of other parts of the body.

References

1. Bahadori M and Liebow AA: Plasma cell granulomas of the lung. *Cancer* 31:191-208, 1973
2. Darby I, Skalli O and Gabbiani G: Alpha-smooth muscle actin is transiently expressed by fibroblast during experimental wound healing. *Lab Invest* 63:21-29, 1990.
3. Davis RE, Warnke RA and Dorfman RF: Inflammatory pseudotumor of lymph nodes. Additional observations and evidence for an inflammatory etiology. *Am J Surg Pathol* 15:744-756, 1991.
4. Facchetti F, De Wolf-Peeters C, De Wever I and Frizzera G: Inflammatory pseudotumor of lymph nodes: immunohistochemical evidence for its fibrohistiocytic nature. *Am J Pathol* 137:281-289, 1990
5. Hollowood K and Fletcher CDM: Pseudosarcomatous myofibroblastic proliferations of the spermatic cord ("Proliferative funiculitis"). Histologic and immunohistochemical analysis of a distinctive entity. *Am J Surg Pathol* 16:448-454, 1992.
6. Hurt MA and Santa Cruz DJ: Cutaneous inflammatory pseudotumor: Lesion resembling "inflammatory pseudotumors" or "plasma cell granulomas" of extracutaneous sites. *Am J Surg Pathol* 14:764-773, 1990
7. Matsubara O, Tan-Liu NS, Kenney RM and Mark EJ: Inflammatory pseudotumors of the lung. Progression from fibrous histiocytoma or to plasma cell granuloma in 32 cases. *Hum Pathol* 19:807-814, 1988.

8. *Mostofi FK and Price EB*: Tumors of the male genital system. Atlas of Tumor Pathology; fasc.8, 2nd ser. Washington D.C.: Armed Forces Institut of Pathology 1973 pp 143-145.
9. *Spencer H*: The pulmonary plasma cell/histiocytoma complex. *Histopathology* 8:903-916, 1984.
10. *Someren A*: "Inflammatory pseudotumor" of liver with occlusive phlebitis. *Am J Clin Pathol* 69:176-181, 1978.
11. *Thompson JE and Van der Walt JD*: Nodular fibrous proliferation (fibrous pseudotumor) of the tunica vaginalis testis. A light, electron microscopic and immunocytochemical study of a case and review of the literature. *Histopathology* 10:741-748, 1986.
12. *Warter A, Satge D and Roeslin N*: Angioinvasive plasma cell granulomas of the lung. *Cancer* 59:435-443, 1987.
13. *Williams SB, Foss RD and Ellis GL*: Inflammatory pseudotumor of the major salivary glands. Clinicopathologic and immunohistochemical analysis of six cases. *Am J Surg Pathol* 16:896-902, 1992.